

# Interactive CardioVascular and Thoracic Surgery

**Apicoaortic valved conduit is a good alternative for aortic stenosis with porcelain  
aorta after off-pump coronary artery bypass grafting**

Yoshiharu Nishimura, Yoshitaka Okamura, Takeshi Hiramatsu and Masahiro Iwahashi  
*Interact CardioVasc Thorac Surg* 2007;6:374-375; originally published online Feb 13,  
2007;

DOI: 10.1510/icvts.2006.150532

The online version of this article, along with updated information and services, is  
located on the World Wide Web at:

<http://icvts.ctsnetjournals.org/cgi/content/full/6/3/374>

*Interactive Cardiovascular and Thoracic Surgery* is the official journal of the European Association  
for Cardio-thoracic Surgery (EACTS) and the European Society for Cardiovascular Surgery  
(ESCVS). Copyright © 2007 by European Association for Cardio-thoracic Surgery. Print ISSN:  
1569-9293.

## Proposal for bail-out procedures - Valves

## Apicoaortic valved conduit is a good alternative for aortic stenosis with porcelain aorta after off-pump coronary artery bypass grafting

Yoshiharu Nishimura\*, Yoshitaka Okamura, Takeshi Hiramatsu, Masahiro Iwahashi

*Department of Thoracic and Cardiovascular Surgery, Wakayama Medical University, Wakayama City, Wakayama, Japan*

Received 18 December 2006; received in revised form 23 January 2007; accepted 23 January 2007

**Abstract**

We report a case of aortic stenosis with porcelain aorta using an apicoaortic valved conduit after 'aortic no touch' off-pump coronary artery bypass grafting. Apicoaortic valved conduit is a good surgical option for this patient to avoid re-entry through the sternum, injury to patent graft and manipulation of the porcelain ascending aorta.

© 2007 Published by European Association for Cardio-Thoracic Surgery. All rights reserved.

**Keywords:** Apicoaortic valved conduit; Porcelain aorta; Off-pump coronary artery bypass grafting

**1. Introduction**

The surgical management of porcelain aorta in patients requiring aortic valve replacement (AVR) remains controversial [1]. We report a successful case using apicoaortic valved conduit (AAVC) for aortic stenosis and porcelain ascending aorta in a patient with a previous history of 'aortic no touch' off-pump coronary artery bypass grafting (CABG).

**2. Case report**

A 74-year-old female was admitted to our hospital with increasing symptoms of congestive heart failure. She had a history of 'aortic no touch' off-pump CABG three years previously with right gastroepiploic artery (GEA) to posterior descending artery and left internal mammary artery (LIMA) to left anterior descending artery in our institute. Although mild aortic stenosis with an aortic valve gradient of 28 mmHg was observed, AVR was not performed in the previous surgery due to porcelain ascending aorta.

On this admission, echocardiogram demonstrated severe aortic stenosis with an aortic valve area of 0.7 cm<sup>2</sup> and aortic valve gradient of 80 mmHg, and mildly reduced left ventricular ejection fraction. Computed tomographic (CT) scan demonstrated a calcified porcelain ascending aorta (Fig. 1a). Cardiac catheterization demonstrated patent LIMA graft and GEA graft (Fig. 1b). The patient was scheduled for AAVC based on the following advantages: (1) there is no need to cross-clamp the porcelain ascending aorta; (2) there is no need for re-entry median sternotomy; (3) patent substernal bypass grafts are protected.

At surgery, anesthetic management consisted of placement of a double-lumen endotracheal tube for single lung ventilation. Posterolateral thoracotomy was performed through the fifth intercostal space. The pericardium was opened and mild adhesions around the apex were dissected. A valved conduit was made using a 19-mm SJM Regent® valve (St. Jude Medical Inc, St. Paul, MN) and a 22-mm Hemashield graft (Maedox, Hemashield, Boston Scientific, Boston, MA) and the distal end of the valved conduit was anastomosed to the descending aorta using a partial occluding clamp. Cardiopulmonary bypass was established using the femoral artery and vein. Eleven interrupted pledgeted 3-0 polypropylene sutures were placed at equidistant sites around the apex to be excised and were threaded through the sewing ring of the Medtronic HANCOCK apical left ventricular connector (Medtronic Inc, Minneapolis, MN). Electrical fibrillation was induced, after which a plug of apical myocardium was removed by a HANCOCK trocar blade. The left ventricular connector was immediately inserted and secured by the eleven previous stitches with reinforcement by continuous 4-0 polypropylene suture. The heart was defibrillated. The left ventricular connector and the valved graft were then anastomosed. The patient was easily weaned from cardiopulmonary bypass. The ventricular fibrillation time was 13 min and total cardiopulmonary bypass time was 78 min.

The postoperative course was uncomplicated. CT scan demonstrated an intact and unobstructed AAVC (Fig. 2). Postoperative echocardiogram demonstrated reduced aortic valve gradient of 23 mmHg. Postoperative blood flow analysis using cine magnetic resonance imaging demonstrated 2.6 l/min through the aortic valve and 3.0 l/min through AAVC.

\*Corresponding author. Tel.: +81-73-441-0615; fax: +81-73-446-4761.

E-mail address: nishim-y@wakayama-med.ac.jp (Y. Nishimura).

© 2007 Published by European Association for Cardio-Thoracic Surgery

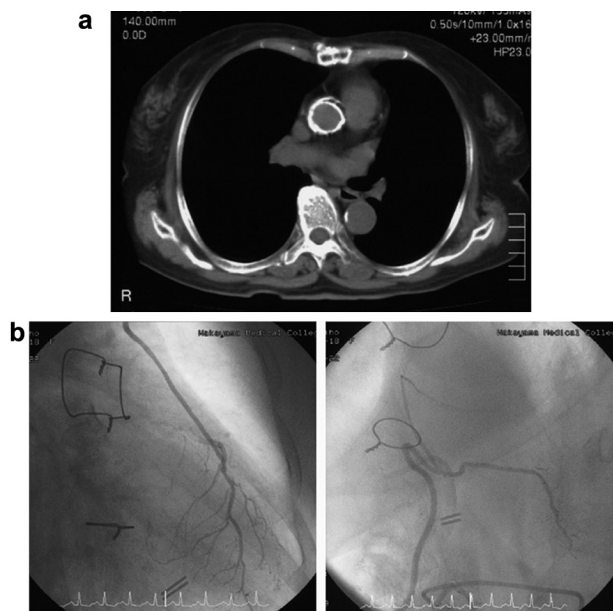


Fig. 1. (a) Preoperative computed tomography demonstrated porcelain ascending aorta. (b) Preoperative coronary angiography demonstrated patent LIMA (left) and GEA (right) graft. LIMA: left internal mammary artery; GEA: gastroepiploic artery.

### 3. Discussion

Progression of aortic stenosis is increasingly encountered in patients demonstrating mild aortic valve gradient at the time of CABG [2]. The risk of AVR after CABG is still high. The main intraoperative problems consist of re-entry median sternotomy, damage to the substernal patent graft and insufficient myocardial protection [2].

The surgical procedure for a patient with porcelain aorta can be difficult in cardiac surgery. If only CABG is required, 'aortic no touch' off-pump technique can be used to avoid cross clamping of the porcelain aorta. However, surgical management of the porcelain aorta in patients requiring AVR is much more complex. Although the surgical procedure previously used included AAVC [3, 4], endarterectomy of the ascending aorta [1, 5] and replacement of ascending aorta using deep hypothermic circulatory arrest, the latter two procedures are extensive and complex surgeries for patients who are often elderly and complicated by other diseases.

In our case, AAVC was successfully performed and was a good surgical option for aortic stenosis after off-pump CABG to avoid re-entry through the sternum, injury to patent LIMA graft and manipulation of the porcelain ascending aorta, and the procedure was successfully performed.

Although AAVC can be performed off-pump with recent modification [6], the most commonly used method for AAVC

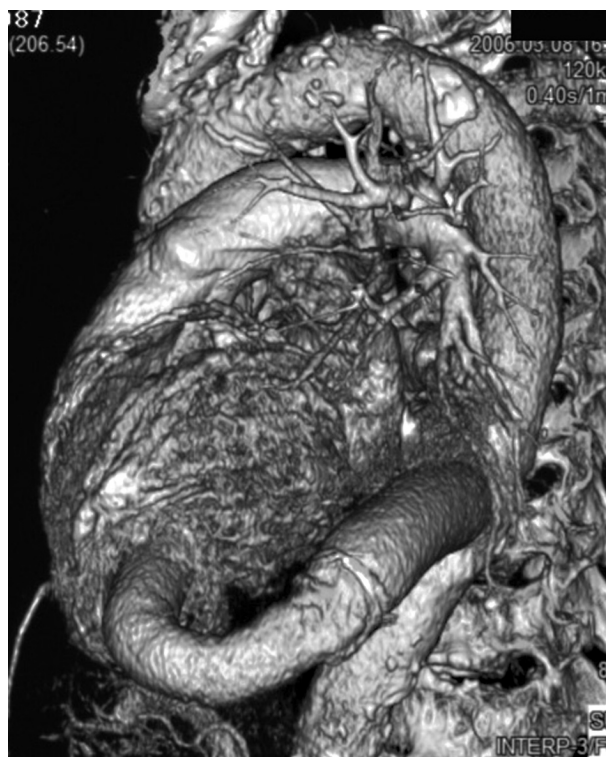

Fig. 2. Postoperative computed tomography after AAVC insertion demonstrated unobstructed conduit.

placement is using CPB either in the arrested or fibrillating heart. Although CPB was used in our patient, AAVC is less invasive compared to other possible AVR procedures.

In conclusion, AAVC is a good alternative for aortic stenosis with porcelain aorta and substernal patent graft after off-pump CABG.

### References

- [1] Svenson LG, Sun J, Cruz HA, Shahian DM. Endarterectomy for calcified porcelain aorta associated with aortic valve stenosis. *Ann Thorac Surg* 1996;61:149–152.
- [2] Shanmugam G. Aortic valve replacement following previous coronary surgery. *Eur J Cardiothorac Surg* 2005;28:731–735.
- [3] Lockowandt U. Apicoaortic valved conduit: potential for progress. *J Thorac Cardiovasc Surg* 2006;132:796–801.
- [4] Sweeney MS, Walker WE, Cooley DA, Reul GJ. Apicoaortic conduits for complex left ventricular outflow obstruction: 10-year experience. *Ann Thorac Surg* 1986;42:609–611.
- [5] Shapira OM, Cruz HA, Shemin RJ. Endarterectomy of the ascending aorta: an alternative method in patients with extensively calcified (porcelain) aorta requiring aortic valve replacement. *J Card Surg* 1997;12:160–164.
- [6] Vassiliades T. Off-pump apicoaortic conduit insertion for high-risk patients with aortic stenosis. *Eur J Cardiothorac Surg* 2003;23:156–158.

**Apicoaortic valved conduit is a good alternative for aortic stenosis with porcelain aorta after off-pump coronary artery bypass grafting**

Yoshiharu Nishimura, Yoshitaka Okamura, Takeshi Hiramatsu and Masahiro Iwahashi  
*Interact CardioVasc Thorac Surg* 2007;6:374-375; originally published online Feb 13, 2007;

DOI: 10.1510/icvts.2006.150532

**This information is current as of December 18, 2007**

<b>Updated Information &amp; Services</b>	including high-resolution figures, can be found at: <a href="http://icvts.ctsnetjournals.org/cgi/content/full/6/3/374">http://icvts.ctsnetjournals.org/cgi/content/full/6/3/374</a>
<b>References</b>	This article cites 6 articles, 5 of which you can access for free at: <a href="http://icvts.ctsnetjournals.org/cgi/content/full/6/3/374#BIBL">http://icvts.ctsnetjournals.org/cgi/content/full/6/3/374#BIBL</a>
<b>Subspecialty Collections</b>	This article, along with others on similar topics, appears in the following collection(s): <b>Coronary disease</b> <a href="http://icvts.ctsnetjournals.org/cgi/collection/coronary_disease">http://icvts.ctsnetjournals.org/cgi/collection/coronary_disease</a> <b>Valve disease</b> <a href="http://icvts.ctsnetjournals.org/cgi/collection/valve_disease">http://icvts.ctsnetjournals.org/cgi/collection/valve_disease</a>
<b>Permissions &amp; Licensing</b>	Requests to reproducing this article in parts (figures, tables) or in its entirety should be submitted to: <a href="mailto:icvts@ejcts.ch">icvts@ejcts.ch</a>
<b>Reprints</b>	For information about ordering reprints, please email: <a href="mailto:icvts@ejcts.ch">icvts@ejcts.ch</a>

# Interactive CardioVascular and Thoracic Surgery